

ONCOGENIC OSTEOMALACIA, YOU SAY? BETTER START LOOKING THEN—A CASE REPORT

Vijay AP, Tan ATB, Suhaida AM, Chan SP

Department of Medicine, Faculty of Medicine, University of Malaya, Kuala Lumpur, Malaysia.

ABSTRACT:

Tumour-induced or oncogenic osteomalacia (OOM) is a rare paraneoplastic syndrome characterized by bone pain and muscle weakness. A biochemical profile consisting of normocalcaemia, hypophosphataemia, phosphaturia, increased serum alkaline phosphatase and inappropriately low serum levels of 1, 25-dihydroxyvitamin-D is diagnostic. OOM is usually caused by an osseous or soft-tissue tumour of mesenchymal origin that secretes phosphaturic substances leading to increased urinary phosphate wasting. These tumours are small and slow growing. The diagnosis continues to be easily missed and when eventually made, localization of the tumour can be difficult. We describe the case of a young man who presented with severe generalized pain associated with muscle weakness. He was extensively investigated and eventually diagnosed to have OOM 3 years after initial presentation. Specialized investigations were necessary to localize the offending tumour. (*JUMMEC 2010; 13 (1): 63-68*)

KEYWORDS: *oncogenic osteomalacia, tumour-induced osteomalacia, hypophosphataemic osteomalacia.*

Case Report

An ethnic Chinese male welder aged 32 initially presented to an orthopaedic surgeon complaining of gradually worsening low back pain associated with weakness of his lower limbs after a fall at home eight months earlier. Magnetic Resonance Imaging (MRI) of the lumbar spine showed a prolapsed intervertebral disc at the L5/S1 level. He, subsequently, underwent a discectomy. Post-operatively, MRI of the spine was reported as normal, however, his symptoms persisted and in fact worsened with pain involving his upper limbs especially the right elbow. The generalized musculoskeletal pain and weakness limited his movement. He complained of difficulty rising from his chair. He required a walking aid, became housebound and was unable to work.

He lived with his parents and there was no family history of malignancy, bone disease or fractures. He had no dietary restrictions. He smoked about five cigarettes and consumed alcohol, three cans of beer daily.

He consulted a neurologist a year after his spine operation. Lumbar puncture and cerebrospinal fluid examination, nerve conduction studies, electromyogram and somatosensory evoked potentials were normal. MRI imaging of the brain, cervical and

lumbar spine showed no significant abnormality. He was then referred to a rheumatologist and given a trial of corticosteroids empirically, dexamethasone 4mg TDS for 1 week for suspected connective tissue disease but did not improve.

Skeletal survey radiographs showed multiple lytic bony lesions proximally and distally in the long bones of all four limbs with some pathological fractures more marked over the right proximal radius (Figure 1). ^{99m}Tc-methylene diphosphonate bone scintigraphy showed multiple symmetrical foci of increased uptake in the articular surfaces of his shoulders, hips, knees, several ribs bilaterally and the right elbow joint, consistent in hindsight with Looser's zones/fractures (Figure 2). (26) Computerized tomogram (CT) of the neck, thorax, abdomen and pelvis was normal.

Correspondence:

Vijay Ananda K.Paramasvaran
Department of Medicine
Faculty of Medicine
University of Malaya
50603 Kuala Lumpur, Malaysia.
E-mail: vijayananda@um.edu.my

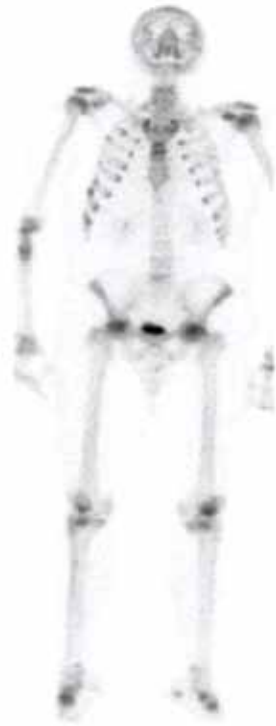

Figure 1: ^{99m}Tc-methylene diphosphonate bone scintigraphy (anterior view) shows multiple abnormal foci of increased uptake. (Dark areas)

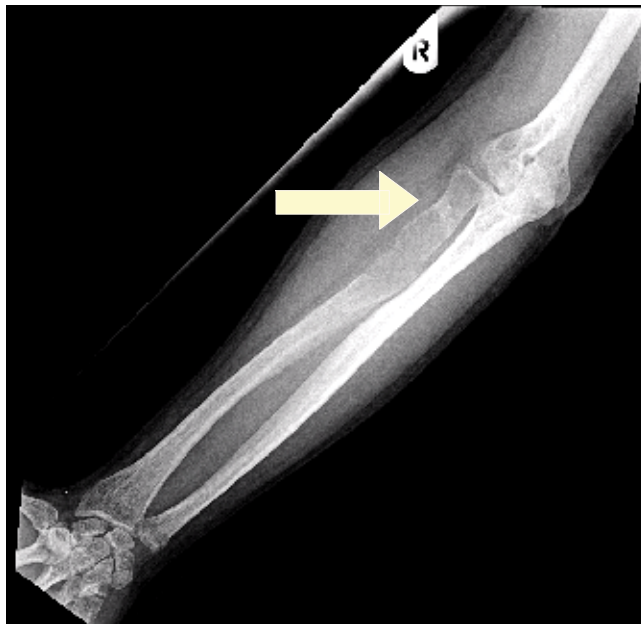

Figure 2: Radiograph of the right radius and ulna shows a lytic lesion at the proximal radius with a healing pathological fracture. (Arrow)

Subsequently, he was referred to an orthopaedic oncologist with the presumptive diagnosis of primary or metastatic bone malignancy. Core needle bone biopsy of the right radius showed features suggestive of osteo-

fibrous dysplasia or reactive bone formation. Diagnosis of myeloma or other haematological malignancy was excluded after appropriate investigations. Review of his biochemistry at this stage prompted an endocrinology consult to exclude metabolic bone disease.

Physical examination revealed an alert, well-nourished man who was unable to walk unaided. His weight was 94kg and height was 160cm with no obvious skeletal deformity. He had gained 10kg due to immobility attributed to his illness. There was no muscle wasting. Grading of power was difficult as movement was limited by musculoskeletal pain in all four limbs. Proximal myopathy was evident; power was 4/5 at the hips and shoulders and 5/5 distally. Passive movement of his limbs and palpation of his ribs also caused pain. He had no sensory deficit and was not incontinent. Knee, ankle, biceps, triceps and supinator reflexes were brisk bilaterally. Central nervous, cardiovascular, respiratory and abdominal systems examination was normal.

Full blood count, erythrocyte sedimentation rate, renal, liver and thyroid hormone profile as well as plasma protein electrophoresis urinalysis and urine for Bence-Jones protein were normal. Serum alkaline phosphatase (ALP) was elevated 302 IU/l (25-100 IU/L), calcium 2.31 µmol/l (2.2-2.6 µmol/L), albumin 36 g/L (35-50 g/L), phosphate was low 0.5 mmol/L (0.8-1.5 mmol/L), intact parathyroid hormone (iPTH) 7.4 pmol/L (1.1-7.3 pmol/L), 24 hour urinary phosphate was inappropriately normal 16.7 mmol/24H (15-50 mmol/24H)- indicating urinary phosphate wasting in the presence of hypophosphataemia, 24 hour urinary calcium excretion 3 mmol/24H (2.2-7.5 mmol/24H) and 25-hydroxyvitamin-D low 35 nmol/L (60-160 nmol/L). Serum 1, 25-dihydroxyvitamin D was not assayed.

He was diagnosed to have hypophosphataemic osteomalacia, most likely due to oncogenic osteomalacia (OOM). He was commenced on oral neutral phosphate solution 45 mls TID, calcitriol (1,25-dihydroxycholecalciferol) 0.25 µg BID and calcium carbonate 1 g BID. Despite treatment, his serum phosphate remained low and symptoms unchanged. His compliance to this regime was questionable.

A search for the primary tumour was initiated. First, he was referred to an otorhinolaryngologist and endoscopic examination revealed a small (0.5 x 0.5 cm) soft tissue nasopharyngeal mass which was surgically

removed but this did not lead to biochemical or clinical improvement. Histopathology showed fragments of seromucinous glands and lymphoid tissue partially covered by respiratory-type epithelium and stratified squamous epithelium.

Positron Emission/Computerized Tomogram using 17.3 mCi (640 MBq) fluorodeoxy-D-glucose (PET/CT-F-18-FDG) was performed which revealed an area of increased uptake and a corresponding lesion at the superior posterior aspect of the right arm. (Figures 3 and 4) Clinical examination revealed a small firm mass. It was surgically removed resulting in prompt normalization of his biochemical parameters. Macroscopically a 3 cm x 1.5 cm x 1.5 cm mass of fibrofatty tissue was excised. Microscopy revealed a lesion consisting of plump proliferating fibroblasts showing mild cellular pleomorphism and mitosis with scattered multinucleated giant cells. An area of osteoid formation continuing into an area of lamellar bone was also noted.

Discussion

McCance described a patient in 1947 whose vitamin D-resistant osteomalacia was cured by resection of a benign osteoid tumour of the femur (1). OOM is characterized by the biochemical profile of low serum phosphate, normal calcium, elevated ALP, low plasma 1, 25-dihydroxyvitamin-D, increased or inappropriate 24 hour urinary excretion of phosphate

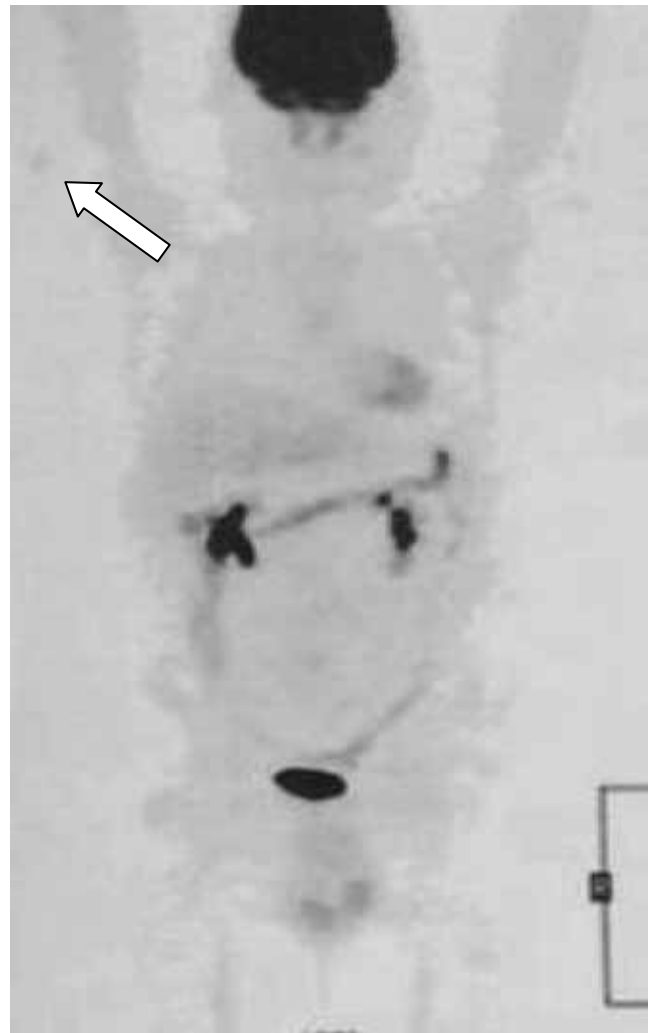

Figure 3: PET F-18-FDG coronal image shows abnormal increased uptake at the superior posterior aspect of the right arm. (Arrow)

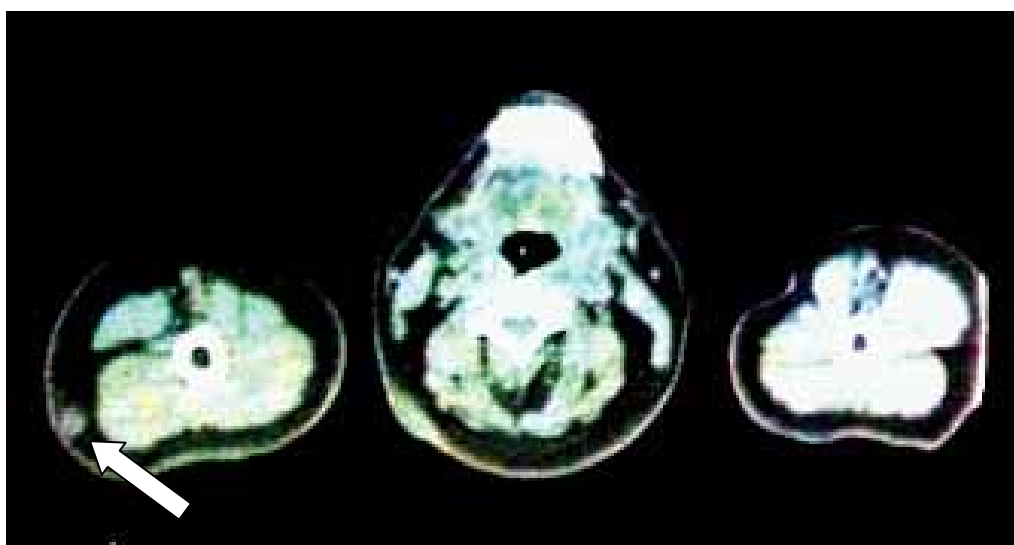


Figure 4: Corresponding CT image shows a lesion at the superior posterior aspect of the right arm. (Arrow)

Table 1: Causes of hypophosphataemic osteomalacia

Inherited causes	Acquired causes
X-linked hypophosphataemic rickets (associated with loss of function of PHEX)	Oncogenic osteomalacia
Autosomal dominant hypophosphataemic rickets (mutation of FGF-23 gene)	Vitamin D deficiency
Autosomal recessive hypophosphataemic rickets (mutation of dentin matrix protein)	Fanconi’s syndrome
	Aluminum ingestion (reduces gastrointestinal absorption of phosphate)

and osteomalacia (2). Serum iPTH is usually normal or mildly elevated (3). Our patient had biochemical features consistent with the diagnosis. Differential diagnoses of hypophosphataemic osteomalacia are shown (Table 1).

Common causes of osteomalacia include phosphate depletion and disorders of vitamin D metabolism. Elevated ALP is a nonspecific finding consistent with bone fracture from any cause. It does rule out hypophosphatasia, a rare heritable cause of osteomalacia, which presents in adulthood with recurrent metatarsal stress fractures or symptomatic chondrocalcinosis. Hypophosphataemia, caused by renal phosphate wasting is normally a potent stimulator of 1, 25-dihydroxyvitamin D production. Low levels of 1, 25-dihydroxyvitamin D however is not diagnostic of oncogenic osteomalacia. Low 1, 25-dihydroxyvitamin D levels combined with severe hypophosphataemia suggest rare disorders that cause both renal phosphate wasting and down regulation of 25-hydroxyvitamin D-1- α -hydroxylase resulting in osteomalacia. An inherited cause is unlikely in our patient given no family history of metabolic bone disease and advanced age at presentation, suggesting an acquired disorder is more likely (4, 5). Fanconi’s syndrome, or renal phosphate wasting associated with glycosuria, aminoaciduria, hyperuricosuria and type-2 renal tubular acidosis is usually inherited but may be acquired. Causes include myeloma, Sjogren’s syndrome or heavy metal exposure. Uric acid and bicarbonate were normal. Urinalysis did not show glycosuria. Low 25-hydroxyvitamin D is not a feature of OOM. We hypothesize that the low levels seen in this patient may have been the result of long term lack of sun exposure due to immobility.

Patients with OOM as in this case typically have muscular weakness and bone pain that progresses gradually over months to years and can resemble a systemic disease or neuromuscular disorder resulting in diagnostic delay. OOM should be considered if radiographs demonstrate Looser’s zones and malnutrition as a cause of osteomalacia has been excluded. There should be no gastrointestinal or genitourinary problem to account for the abnormal biochemical profile (6-8).

The primary tumour is usually of mesenchymal origin with prominent fibrous and vascular characteristics. Hemangiopericytoma, benign angiofibroma, giant cell tumours of bone and soft tissue, tumours associated with multiple myeloma, chronic lymphocytic leukemia, fibrous dysplasia of bone and neurofibromatosis have been described to cause OOM (2, 7-10). The tumor is often small, benign and slow growing; usually located over the extremities, head and neck. 50% of the tumours are located in the skeleton and not easily detectable on physical examination or routine radiography accounting for delay in diagnosis (3, 11-13).

Dual-energy x-ray absorptiometry may show low bone density, consequence of decreased mineralization of bone due to osteomalacia, not osteoporosis (4). T2-weighted short-tau inversion-recovery (STIR) MRI,²⁰¹ thallium and whole body ^{99m} technetium sestamibi scintigraphy have been recommended for tumour search, as well as ¹¹¹ indium pentetreotide or octreotide scintigraphy (7, 8, 11, 14, 15). Tumours frequently express somatostatin receptor subtype-2 and bind ¹¹¹ indium labelled octreotide. Not all mesenchymal tumours causing OOM are positively identified by this

method (17). We did not have this facility. Successful tumour localization using PET/CT-F-18-FDG when multiple other imaging tests have failed has been described with increasing frequency (16).

The tumour produces fibroblast growth factor 23 (FGF-23), phosphatonin or phosphaturic hormone which underlies all the metabolic abnormality associated with hypophosphataemic syndrome. FGF-23 inhibits renal phosphate transport and 1, 25-dihydroxyvitamin D production (17-21). The injection of FGF-23 transfected cells into mice results in the characteristic features of OOM (3). However FGF-23 level is also increased in patients with X-linked hypophosphataemic rickets by the loss of function of the phosphate regulating gene with homologies to endopeptidase on the X chromosome (PHEX). It is speculated that PHEX protein functions as a protease to cleave FGF-23 and inactivate its function (3, 22, 23). Some other factors such as matrix extracellular phosphoglycoprotein and secreted frizzled-related protein 4 have also been implicated in the pathogenesis of OOM. Successful selective venous sampling for FGF-23 with MRI to localize tumours has been described (13, 16).

The clinical course of OOM is dramatically affected by removal of the causative tumour, resulting in rapid resolution of biochemical abnormalities. There is gradual improvement of bone mineralization and symptoms (2, 8, 10). Phosphate 1-4 grams/day in divided doses and 1, 25-dihydroxyvitamin D replacement is recommended but with limited success (3, 8). Long term complications of treatment include secondary hyperparathyroidism and ectopic calcification, including nephrocalcinosis (24). As short term treatment, octreotide has been shown to rapidly correct serum phosphate levels and ALP activity in patients with tumours that were detected by octreotide scintigraphy (25). Others report failure to normalize serum phosphate but successful suppression of serum FGF-23 with octreotide therapy (26). CT guided radio frequency tumour ablation has been described; it may offer an effective, less invasive alternative to classical surgery especially for inaccessible tumours (27).

Conclusion

Diagnosis of OOM requires recognition of the typical clinical, biochemical and radiological features. Other conditions associated with hypophosphataemia must

be excluded. Follow up with surveillance for tumour recurrence and biochemical monitoring is warranted. Our patient presented with the typical features of OOM and followed the classical route; with delay in obtaining the final diagnosis and difficulty locating the primary causative tumour. Fortunately, he responded promptly with normalization of phosphate and alkaline phosphatase accompanied by resolution of pain after tumour resection.

References

1. McCance RA. Osteomalacia with Looser's nodes (Milkman's syndrome) due to a raised resistance to vitamin D acquired about the age 15 years. *Q J Med* 1947; 16: 33-46.
2. Cai Q, Hodgson SF, Kao PC, *et al.* Brief report: inhibition of renal phosphate transport by a tumor product in a patient with oncogenic osteomalacia. *N Engl J Med* 1994; 330: 1645-1649.
3. Carpenter TO. Oncogenic osteomalacia – A complex dance of factors. *N Engl J Med* 2003; 348:1705-1708.
4. Reilly BM, Hart PD, Mascarell S, Chatrath H. A question well put. *N Eng J Med* 2009; 360: 1446-1451.
5. Jan de Beur SM, Levine MA. Molecular pathogenesis of hypophosphatemic rickets. *J Clin Endocrinol Metab* 2002; 87: 2467-2473.
6. Edminster KA, Sundaram A. Oncogenic Osteomalacia. *Semin Musculoskelet Radiol* 2002; 6: 191-196.
7. Sundaram A, McCarthy EF. Oncogenic osteomalacia. *Skeletal Radiol* 2000; 29: 117-124.
8. Jan de Beur SM. Tumor induced osteomalacia. *JAMA* 2005; 294:1260-1267.
9. Weidner N, Santa Cruz D. Phosphaturic mesenchymal tumors. A polymorphous group causing osteomalacia or rickets. *Cancer* 1987; 59: 1442-1454.
10. Folpe AL, Fanburg-Smith JC, Billings SD, *et al.* Most osteomalacia-associated mesenchymal tumors are a single histopathologic entity: an analysis of 32 cases and a comprehensive review of the literature. *Am J Surg Pathol* 2004; 28(1): 1-30.

11. Fukumoto S, Takeuchi Y, Nagano A, Fujita T. Diagnostic utility of magnetic resonance imaging skeletal survey in a patient with oncogenic osteomalacia. *Bone* 1999; 25: 375-377.
12. Drezner MK. Tumour associated rickets and osteomalacia. Primer on the Metabolic Bone Diseases and Disorders of Mineral Metabolism. 3rd ed. Philadelphia: Lippincott-Raven, 1996: 319-325.
13. Takeuchi Y, Suzuki H, Ogura S, et al. Venous sampling for fibroblast growth factor-23 confirms preoperative diagnosis of tumor-induced osteomalacia. *J Clin Endocrinol Metab* 2004; 89: 3979-3982.
14. Gershinsky M, Croitoru S, Dickstein G, et al. Imaging of oncogenic osteomalacia. *IMAJ* 2007; 9: 566-567.
15. Rhee Y, Lee JD, Shin KH, et al. Oncogenic osteomalacia associated with mesenchymal tumour detected by indium-111 octreotide scintigraphy. *Clin Endocrinol (Oxf)* 2001; 54: 551-554.
16. Khadgawat R, Singh Y, Kansara S, Tandon N, Bal C, Seith A, Kotwal P. PET/CT localisation of a scapular haemangiopericytoma with tumour-induced osteomalacia. *Singapore Med J* 2009; 50(2): 55-57.
17. Brame LA, White KE, Econs MJ. Renal phosphate wasting disorders: clinical features and pathogenesis. *Semin Nephrol* 2004; 24:39-47.
18. Kumar R. Tumor-induced osteomalacia and the regulation of phosphate homeostasis. *Bone* 2000; 27: 333-338.
19. Schiavi SC, Moe OW. Phosphatonins: a new class of phosphate-regulating proteins. *Curr Opin Nephrol Hypertens* 2002; 11: 423-430.
20. Nelson AE, Bligh RC, Mirams M, et al. Fibroblast growth factor-23: A clinical marker for oncogenic osteomalacia. *J Clin Endocrinol Metab* 2003; 88: 408-494.
21. Sommer S, Berndt T, Craig T, Kumar R. The phosphatonins and the regulation of phosphate transport and vitamin D metabolism. *J Steroid Biochem Mol Biol* 2007; 103: 497-503.
22. Jonsson KB, Zahradnik R, Larsson T, et al. Fibroblast growth factor 23 in oncogenic osteomalacia and X-linked hypophosphataemia. *N Engl J Med* 2003; 348: 1656-1663.
23. Shimada T, Muto T, Urakawa I, et al. Mutant FGF-23 responsible for autosomal dominant hypophosphataemic rickets is resistant to proteolytic cleavage and causes hypophosphataemia in vivo. *Endocrinology* 2002; 143: 3179-3182.
24. Huang QL, Feiq DS, Blackstein ME. Development of tertiary hyperparathyroidism after phosphate supplementation in oncogenic osteomalacia. *J Endocrinol Invest* 2000; 23: 263-267.
25. Seijas R, Ares O, Sierra J, Pérez-Dominguez M. Oncogenic osteomalacia: two case reports with surprisingly different outcomes. *Arch Orthop Trauma Surg* 2009; 129: 533-539.
26. Elston MS, Stewart IJ, Clifton-Bligh R, Conaglen JV. A case of oncogenic osteomalacia with preoperative secondary hyperparathyroidism: description of the biochemical response of FGF23 to octreotide therapy and surgery. *Bone* 2007 Jan; 40: 236-241.
27. Hesse E, Rosenthal H, Bastian L. Radiofrequency ablation of a tumor causing oncogenic osteomalacia. *N Engl J Med* 2007; 357: 422-424.